

IMAGES AND VIDEOS

Late thrombosis of a mitral bioprosthetic valve with associated massive left atrial thrombus

Preetham R Muskula, Rigoberto Ramirez, A Michael Borkon and Michael L Main

Saint Luke's Mid America Heart Institute, Kansas City, Missouri, USA

Correspondence
should be addressed
to M L Main

Email
mmain@saint-lukes.org

Summary

An 84-year-old man presented 5 years after bioprosthetic mitral valve replacement with three months of worsening dyspnea on exertion. A new mitral stenosis murmur was

noted on physical examination, and an electrocardiogram revealed newly recognized atrial fibrillation. Severe mitral stenosis (mean gradient=13 mmHg) was confirmed

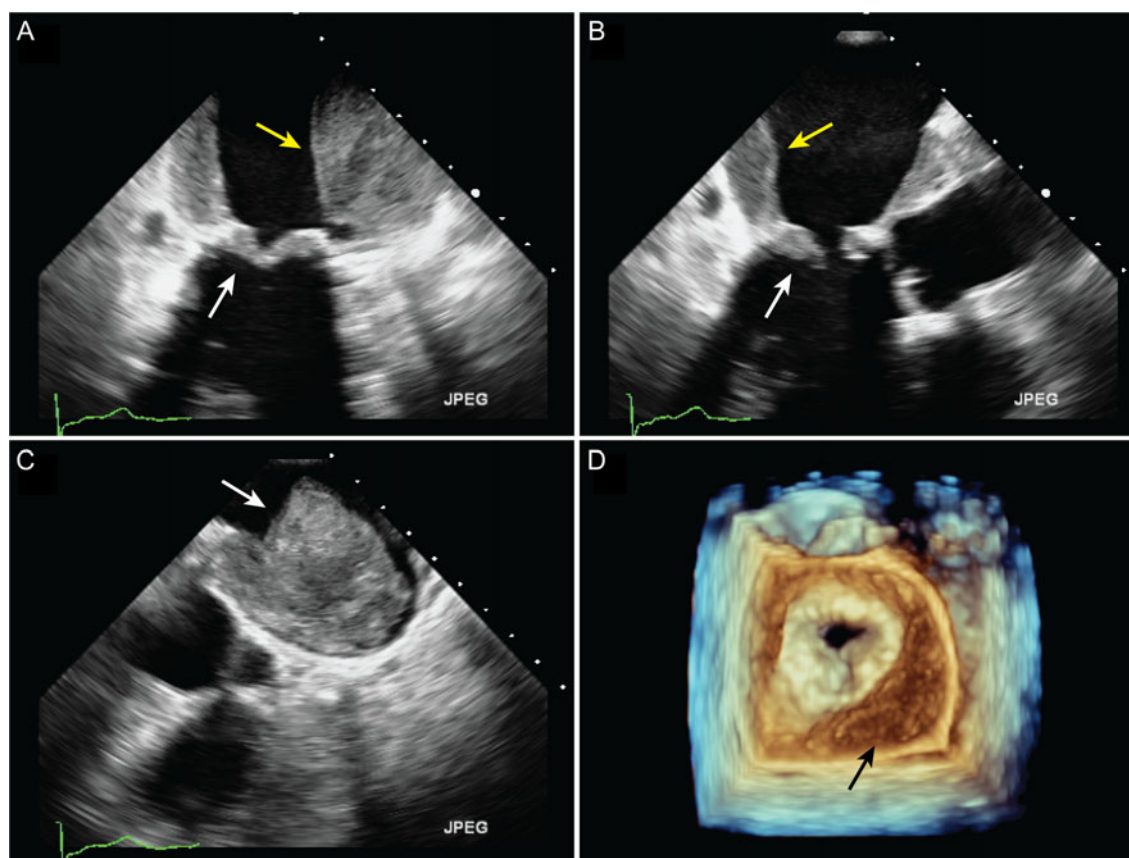


Figure 1

(A) Mid-esophageal 2-chamber TEE image reveals a massive left atrial mural thrombus (yellow arrow) and markedly thickened bioprosthetic mitral leaflets (white arrow). (B) Mid-esophageal long-axis TEE image reveals a massive left atrial mural thrombus (yellow arrow) and markedly thickened bioprosthetic mitral leaflets (white arrow). (C) Off-axis TEE view of the left atrium reveals a massive left atrial thrombus (white arrow). (D) Three-dimensional en face view (left atrial perspective) of the stenotic bioprosthetic mitral valve. Note the left atrial mural thrombus (black arrow).

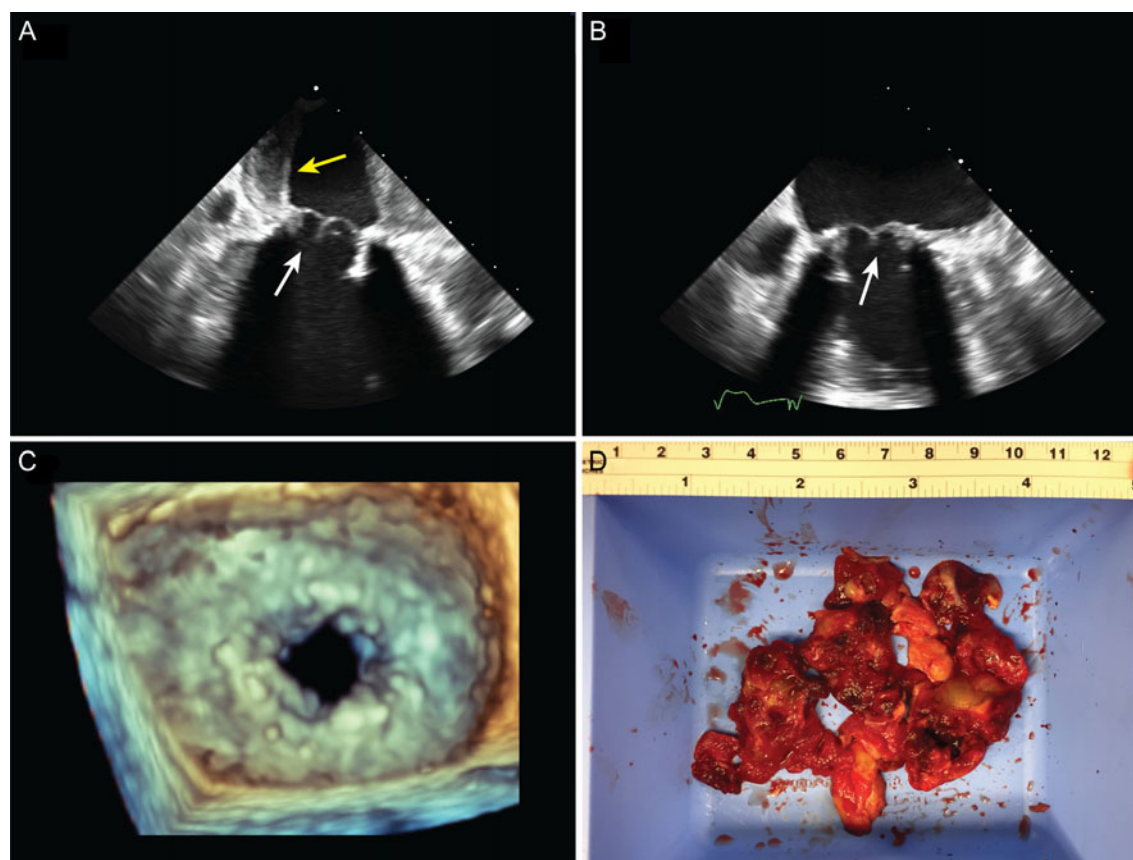


Figure 2

(A) Intraoperative mid-esophageal 2-chamber TEE image demonstrates thin and pliable bioprosthetic mitral leaflets (white arrow) after 5 days of intravenous heparin (compare to Fig. 1A and B). The left atrial thrombus remains (yellow arrow). (B) Intraoperative mid-esophageal TEE image after extraction of the left atrial thrombus (compare to Fig. 2A). The bioprosthetic mitral leaflets appear normal (white arrow). (C) Three-dimensional en face view (left atrial perspective). The mitral valve area is improved (compared to Fig. 1D), and the left atrial thrombus has been extracted. (D) Left atrial thrombus after resection.

by transthoracic echocardiography. Transesophageal echocardiography revealed markedly thickened mitral bioprosthetic leaflets with limited mobility, and a massive left atrial thrombus (>4cm in diameter) (Fig. 1A, B, C, D and Videos 1, 2, 3 and 4). Intravenous heparin was initiated, and 5 days later, he was taken to the operating room for planned redo mitral valve replacement and left atrial thrombus extraction. Intraoperative transesophageal echocardiography revealed near-complete resolution of the bioprosthetic leaflet thickening, and a mean mitral gradient of only 3 mmHg (Fig. 2A, B, C and Videos 5, 6 and 7). The patient underwent resection of the massive left atrial thrombus (Fig. 2D) but did not require redo mitral valve replacement. He was initiated on heparin (and transitioned to warfarin) early in the post-operative period, with complete resolution of dyspnea on exertion at 3-month follow-up. Bioprosthetic valve thrombosis is

increasingly recognized as a cause of early prosthetic valve dysfunction (1, 2). This case illustrates that bioprosthetic valve thrombosis may occur years after valve replacement; therefore, any deterioration in a patient's clinical status (new-onset dyspnea, heart failure or atrial fibrillation) warrants a thorough evaluation of the bioprosthetic valve with transesophageal echocardiography. In this case, initiation of anticoagulation obviated the need for redo mitral valve replacement.

Video 1

Mid-esophageal 2-chamber TEE image reveals a massive left atrial mural thrombus and markedly thickened bioprosthetic mitral leaflets. View Video 1 at <http://movie-usa.glencoesoftware.com/video/10.1530/ERP-17-0004/video-1>.

Video 2

Mid-esophageal long axis TEE image reveals a massive left atrial mural thrombus and markedly thickened bioprosthetic mitral leaflets. View Video 2 at <http://movie-usa.glencoesoftware.com/video/10.1530/ERP-17-0004/video-2>.

Video 3

Off-axis TEE view of the left atrium reveals a massive left atrial thrombus. View Video 3 at <http://movie-usa.glencoesoftware.com/video/10.1530/ERP-17-0004/video-3>.

Video 4

Three-dimensional en face view (left atrial perspective) of the stenotic bioprosthetic mitral valve. Note the left atrial mural thrombus. View Video 4 at <http://movie-usa.glencoesoftware.com/video/10.1530/ERP-17-0004/video-4>.

Video 5

Intraoperative mid-esophageal 2-chamber TEE image demonstrates thin and pliable bioprosthetic mitral leaflets after 5 days of intravenous heparin (compare to Fig. 1A and B). The left atrial thrombus remains. View Video 5 at <http://movie-usa.glencoesoftware.com/video/10.1530/ERP-17-0004/video-5>.

Video 6

Intraoperative mid-esophageal TEE image after extraction of the left atrial thrombus (compare to Fig. 2A). The bioprosthetic mitral leaflets appear normal. View Video 6 at <http://movie-usa.glencoesoftware.com/video/10.1530/ERP-17-0004/video-6>.

Video 7

Three-dimensional en face view (left atrial perspective). The mitral valve area is improved (compared to Fig. 1D), and the left atrial thrombus has been extracted. View Video 7 at <http://movie-usa.glencoesoftware.com/video/10.1530/ERP-17-0004/video-7>.

Declaration of interest

The authors declare that there is no conflict of interest that could be perceived as prejudicing the impartiality of this article.

Funding

This work did not receive any specific grant from any funding agency in the public, commercial, or not-for-profit sector.

Patient consent

Written informed consent has been obtained from the patient.

Author contribution statement

Preetham Muskula and Rigoberto Ramirez wrote the initial manuscript draft. Michael Main served as senior author and revised the manuscript. A Michael Borkon revised the manuscript.

References

- 1 Dangas GD, Weitz JI, Giustino G, Makkar R & Mehran R 2016 Prosthetic heart valve thrombosis. *Journal of the American College of Cardiology* **68** 2670–2689. (doi:10.1016/j.jacc.2016.09.958)
- 2 Egbe AC, Connolly HM, Pellikka PA, Schaff HV, Hanna R, Maleszewski JJ, Nkomo VT & Pislaru SV 2017 Outcomes of warfarin therapy for bioprosthetic valve thrombosis of surgically implanted valves: a prospective study. *JACC: Cardiovascular Interventions* **10** 379–387. (doi:10.1016/j.jcin.2016.11.027)

Received in final form 10 March 2017

Accepted 16 March 2017

Accepted Preprint published online 16 March 2017