

CASE REPORT

Critical aortic stenosis presenting as STEMI

Ying X Gue, Sanjay S Bhandari and Damian J Kelly

Department of Cardiology, Royal Derby Hospital, Derby Hospital NHS Foundation Trust, Derby, UK

Correspondence
should be addressed
to Y X Gue
Email
y.gue@nhs.net

Summary

A 73-year-old male was brought into hospital with chest pain and inferior ST elevation on ECG. The patient immediately proceeded to the catheter lab for primary percutaneous coronary intervention. Angiography did not identify any culprit lesions to account for the patient's electrocardiographic changes and ongoing symptoms of chest pain. Bedside echocardiography revealed critical aortic stenosis. Intra-aortic balloon pump (IABP) was inserted, resulting in resolution of chest pain and ST-segment changes. The patient underwent successful aortic valve (AV) replacement without the need for coronary intervention. This is a rare presentation of critical aortic stenosis (AS) presenting as ST-segment elevation myocardial infarction (STEMI).

Key Words

- ▶ aortic stenosis
- ▶ myocardial infarction
- ▶ echocardiogram

Learning points:

- Aortic stenosis (AS) affects 2–9% of population above 65 years old and increases with age.
- AS induces ischaemia via abnormal cardiac coronary coupling.
- Focused clinical examination in patients with ST-segment elevation myocardial infarction (STEMI) is vital prior to cardiac catheterisation.
- Detection of murmurs should be followed on by an echocardiography examination.
- Other differentials of STEMI include acute aortopathy, endocarditis with embolus, myopericarditis and intracranial haemorrhage.

Background

ST-segment elevation myocardial infarction (STEMI) commonly occurs when a coronary artery becomes totally occluded by a blood clot disrupting blood flow to the myocardium. The UK national registry has shown that out of 80 724 admissions in 2013/2014 with acute coronary syndrome (ACS), 39% had STEMI (1). However, not all cases of STEMI are due to coronary artery occlusion: in this case, critical aortic stenosis (AS) led to inadequate myocardial perfusion in the absence of demonstrable epicardial coronary stenosis or occlusion.

AS is present in 2–9% of general population over the age of 65 years, and its incidence increases with age (2). The risk factors for AS are similar to that of atherosclerosis (age, male sex, smoking, hypertension, and raised lipoprotein and LDL) (3).

Case presentation

A 73-year-old male presented with typical ischaemic chest pain at rest and inferior ST-segment elevation on a

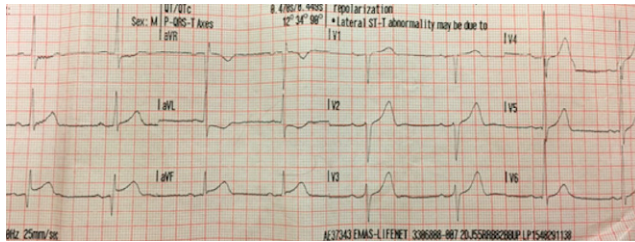


Figure 1
ECG on arrival.

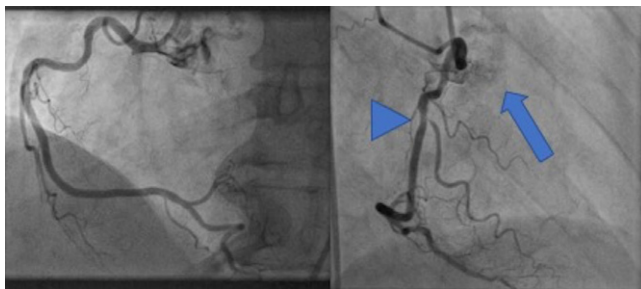


Figure 2
RCA (arrowhead showing diseased segment and arrow showing calcified aortic valve (AV)).

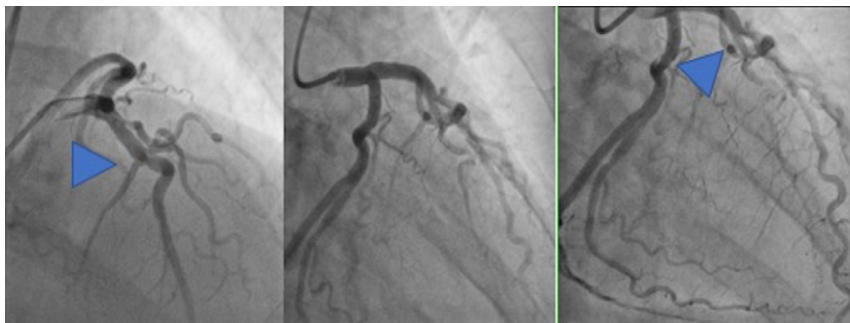


Figure 3
Left-sided coronary angiogram (arrowhead showing diseased segment in LAD).

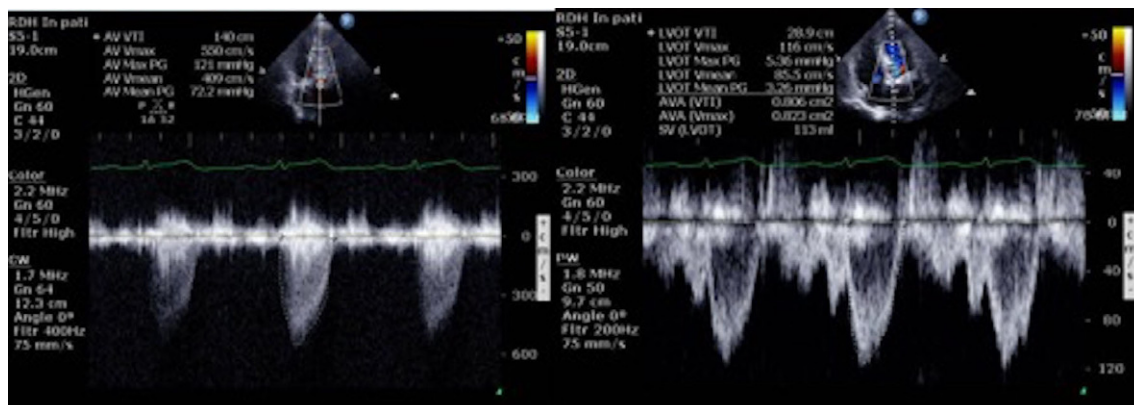


Figure 4
Echocardiogram showing Doppler measurements.

background of exertional chest tightness over a 6-month period. Paramedic ECG (Fig. 1) showed inferior STEMI with voltage criteria for left ventricular hypertrophy (LVH). Past medical history included hypertension and benign prostatic hyperplasia (BPH). The patient's risk factors for coronary artery disease (CAD) included a previous history of smoking and a positive family history of premature cardiovascular disease. Examination revealed an ejection systolic murmur with an absent second heart sound. Given the ECG findings, the patient was brought directly into the cardiac catheterisation lab for coronary angiography and primary percutaneous coronary intervention (PCI).

Investigation

Coronary angiography revealed minimal atheroma within the right coronary artery (RCA) (Fig. 2) and a mild stenosis of the mid left anterior descending (LAD) artery (Fig. 3). Incidentally, heavy calcification was noted on the AV on fluoroscopy (Fig. 2). In view of the ongoing chest

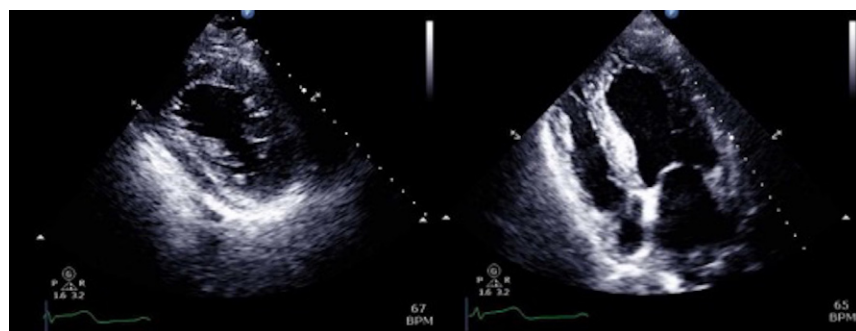


Figure 5
Parasternal short axis (PSAX) and 4-chamber view showing concentric LVH.

pain and persistent ST elevation, a pressure wire study with intravenous adenosine was performed across the LAD lesion which showed a fractional flow reserve (FFR) of 0.90, indicating that the lesion was not significantly flow limiting.

Bedside echocardiography was performed which showed critical AS (V_{\max} 5.5 m/s, Max PG 90 mmHg, Mean PG 72.2 mmHg, AVA 0.8 cm²) (Fig. 4) and evidence of LVH with no regional wall motion abnormalities (Fig. 5). Short axis view (Fig. 6) of the AV revealed a calcified AV with limited mobility and narrow opening.

view of ongoing ischaemic chest pain, with persistent ST-segment elevation and no evidence of coronary occlusion. The case was discussed with the cardiac surgeons and the patient was accepted for urgent AV replacement.

Following insertion of the IABP there was rapid resolution of chest pain and resolution of ST-segment elevation (Fig. 7). The patient underwent emergency AV surgery without bypass grafting. The patient made a good recovery and was symptom-free at 8-week follow-up.

Treatment and outcome

Prior to coronary angiography, the patient was loaded with aspirin and ticagrelor. On identification of critical AS, an intra-aortic balloon pump (IABP) was inserted in

Discussion

This is a rare case of critical AS resulting in significant disruption of normal laminar haemodynamic across the valve (4), which can lead to significant myocardial

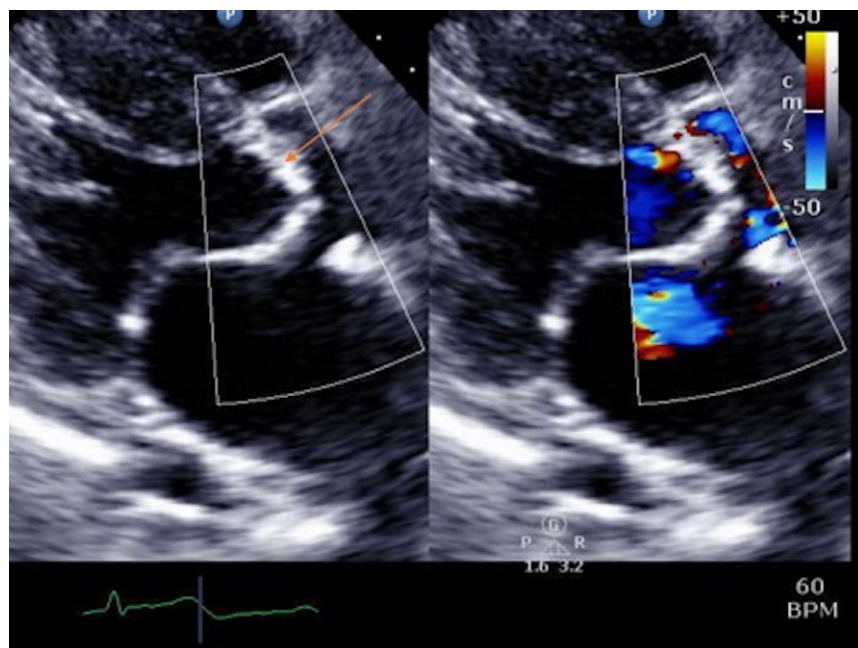


Figure 6
Parasternal long axis view (PLAX) view showing calcified AV (orange arrow).

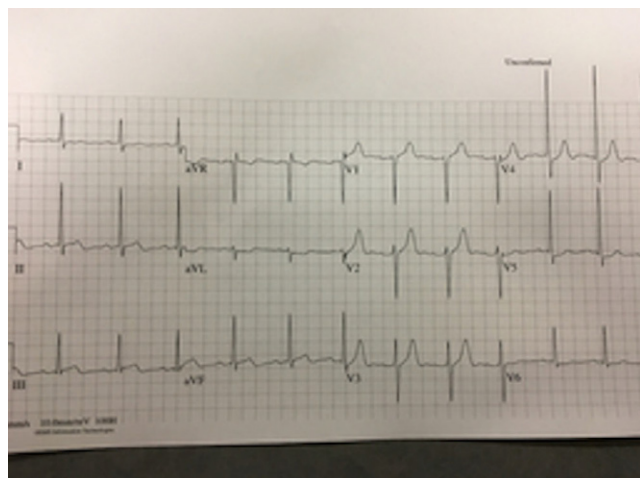


Figure 7
ECG 2 h post IABP.

hypoperfusion in the face of LVH despite unobstructed coronary arteries.

Lumley *et al.* (5) showed that the underlying mechanism for ischaemia in patients with severe AS is due to an abnormal cardiac coronary coupling – the inability to increase blood flow in proportion to cardiac workload resulting in ischaemia. A similar case was published in 2010 by Wayangankar *et al.* (6). However, the patient in this case did exhibit ST-segment elevation.

While plaque rupture may result in STEMI despite the absence of a severe arterial stenosis, the persistence of ECG changes without arterial occlusion and the response to IABP are highly suggestive of a valvular cause for this patient's presentation. Other differentials of STEMI with non-obstructing coronaries include acute aortopathy, endocarditis with embolus, myopericarditis and intracranial haemorrhage.

This case highlights the importance of the correlating clinical examination with focused bedside investigation like echocardiography in the management of patients presenting with chest pain. The European Association of Cardiovascular Imaging and the Acute Cardiovascular Care Association have recommended the use of echocardiography in patients presenting with acute chest pain; however, a level of competency is required for accurate interpretation of the results (7).

Declaration of interest

The authors declare that there is no conflict of interest that could be perceived as prejudicing the impartiality of this case report.

Funding

This work did not receive any specific grant from any funding agency in the public, commercial or not-for-profit sector.

Patient consent

Patient consent was obtained and consent form was signed.

Author contribution statement

Y X G was involved with the patient's care and wrote the case presentation, investigation and treatment outcome. S S B wrote the discussion and learning points of the case. D J K was the consultant in charge of the case and did the final draft.

References

- Weston C, Gavalova L, Whittaker T & Van Leeuwen R 2014 Myocardial Ischaemia National Audit Project. How the NHS cares for patients with heart attack: Annual Public Report April 2013–March 2014. NICOR. Padcreative.
- Faggiano P, Antonini-Canterin F, Baldessin F, Lorusso R, D'Aloia A & Dei Cas L 2006 Epidemiology and cardiovascular risk factors of aortic stenosis. *Cardiovascular Ultrasound* **4** 27. (doi:10.1186/1476-7120-4-27)
- Stewart BF, Siscovick D, Lind BK, Gardin JM, Gottdiener JS, Smith VE, Kitzman DW & Otto CM 1997 Clinical factors associated with calcific aortic valve disease. *Journal of the American College of Cardiology* **29** 630–634. (doi:10.1016/S0735-1097(96)00563-3)
- Gould L & Carebello B 2003 Why angina in aortic stenosis with normal coronary arteriograms? *Circulation* **107** 3121–3123. (doi:10.1161/01.CIR.0000074243.02378.80)
- Lumley M, Williams R, Asress KN, Arri S, Briceno N, Ellis H, Rajani R, Siebes M, Piek JJ, Clapp B, *et al.* 2016 Coronary physiology during exercise and vasodilation in the healthy heart and in severe aortic stenosis. *Journal of the American College of Cardiology* **68** 688–697. (doi:10.1016/j.jacc.2016.05.071)
- Wayangankar SA, Dasari TW, Lozano PM & Beckman KJ 2010 A case of critical aortic stenosis masquerading as acute coronary syndrome. *Cardiology Research and Practice* **2010** article ID 423465. (doi:10.4061/2010/423465)
- Lancellotti P, Price S, Edvardsen T, Cosyns B, Neskovic AN, Dulgheru R, Flachskampf FA, Hassager C, Pasquet A, Gargani L, *et al.* 2015 The use of echocardiography in acute cardiovascular care: recommendations of the European Association of Cardiovascular Imaging and the Acute Cardiovascular Care Association. *European Heart Journal: Cardiovascular Imaging* **16** 119–146. (doi:10.1093/ehjci/jeu210)

Received in final form 4 June 2017

Accepted 6 July 2017

Accepted Preprint published online 6 July 2017