

## IMAGES AND VIDEOS

# Concomitant acute stroke, pulmonary and myocardial infarction due to in-transient thrombus across a patent foramen ovale

Sergio Barros-Gomes MD, Abdallah El Sabbagh MD, Mackram F Eleid MD and Sunil V Mankad MD

Division of Cardiovascular Diseases, Mayo Clinic, Rochester, Minnesota, USA

Correspondence should be addressed to S V Mankad: [mankad.sunil@mayo.edu](mailto:mankad.sunil@mayo.edu)

### Summary

Non-atherosclerotic myocardial infarction (MI) is an important but often misdiagnosed cause of acute MI. Furthermore, non-atherosclerotic MI with concomitant acute stroke and pulmonary embolism due to in-transit thrombus across a patent foramen ovale (PFO) is a rare but potentially fatal combination (1, 2, 3). Early detection of this clinical entity can facilitate delivery of targeted therapies and avoid poor outcome (1, 2). Here, we describe a 68-year-old female with hypertension, tobacco abuse and chronic obstructive pulmonary disease presenting with facial droop, right arm weakness and aphasia. Head computed tomography (CT) without contrast was unremarkable. ECG showed an acute inferolateral ST-elevation MI (Fig. 1, Panel A). As patient presented with both an acute neurological deficit and MI, clinical suspicion of non-atherosclerotic MI was raised and the patient underwent concurrent emergency coronary angiography (CAG) and transesophageal echocardiogram (TEE). TEE revealed highly mobile masses in the left and right atrium (Fig. 1, Panel B and Video 1). The large mass (thrombus or cast of a deep venous thrombus) was caught in a PFO (Fig. 1, Panel C, D, E and Videos 2, 3). A second smaller mass/thrombus was seen on the Eustachian valve near the right atrial/inferior vena cava junction (Fig. 1, Panel F and Video 4). CAG confirmed a 100% occluded distal right posterolateral artery suggestive of an embolic phenomenon. The patient underwent successful thrombectomy, retrieving a large thrombus burden (Fig. 1, Panel G and Videos 5, 6, 7). CT angiography showed occluded internal carotid artery

(Fig. 1, Panel H). Pathology from thrombectomy confirmed fibrin-rich thrombus. The patient had bilateral lower extremity deep vein thrombosis and bilateral diffuse pulmonary embolisms.

#### Video 1

TEE bicaval revealing a highly mobile mass in both atria. View Video 1 at <http://movie-usa.glencoesoftware.com/video/10.1530/ERP-18-0044/video-1>.

#### Video 2

TEE four-chamber view showing the large thrombus that was caught in a PFO. View Video 2 at <http://movie-usa.glencoesoftware.com/video/10.1530/ERP-18-0044/video-2>.

#### Video 3

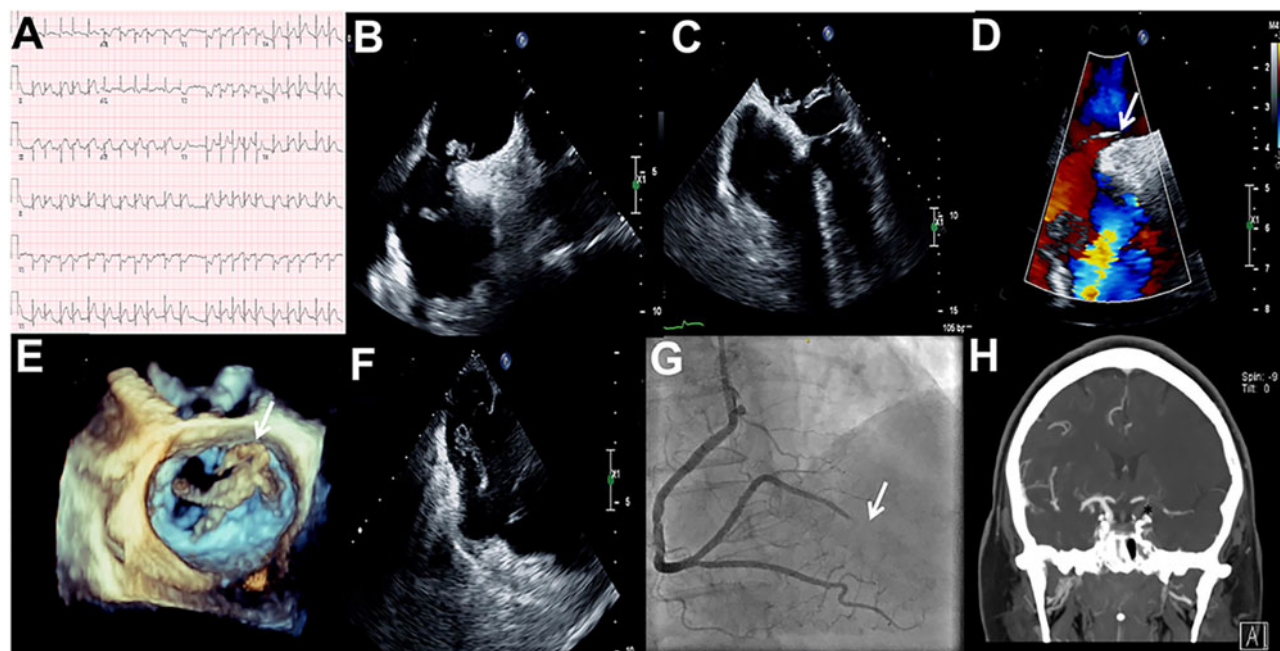
3D-TEE showing a large thrombus in the left atrium. View Video 3 at <http://movie-usa.glencoesoftware.com/video/10.1530/ERP-18-0044/video-3>.

#### Video 4

TEE showing a second smaller thrombus on the Eustachian valve. View Video 4 at <http://movie-usa.glencoesoftware.com/video/10.1530/ERP-18-0044/video-4>.

#### Video 5

CAG confirming 100% occluded distal right posterolateral artery. View Video 5 at <http://movie-usa.glencoesoftware.com/video/10.1530/ERP-18-0044/video-5>.



**Figure 1**

(A) ECG showing an acute inferolateral ST-elevation MI; (B) TEE bicaval view revealing a highly mobile mass in the left and right atrium; (C) TEE four-chamber view showing a large thrombus across a PFO; (D) TEE bicaval with color Doppler showing a shunt across the interatrial septum; (E) 3D-TEE showing irregular shape of the thrombus; (F) TEE at lower-esophageal level showing a second smaller thrombus on the Eustachian valve; (G) CAG confirming 100% occluded distal right posterolateral artery; (H) CT angiography showing occluded internal carotid artery.

## Video 6

CAG during thrombus aspiration. View Video 6 at <http://movie-usa.glencoesoftware.com/video/10.1530/ERP-18-0044/video-6>.

## Video 7

CAG showing restored TIMI III flow in the vessel. View Video 7 at <http://movie-usa.glencoesoftware.com/video/10.1530/ERP-18-0044/video-7>.

## Declaration of interest

The authors declare that there is no conflict of interest that could be perceived as prejudicing the impartiality of this article.

## Funding

This work did not receive any specific grant from any funding agency in the public, commercial, or not-for-profit sector.

## Patient consent

Images are anonymized. Permission to publish was obtained from a relative.

## Author contribution statement

Contribution to the patient care: Sergio Barros-Gomes; Abdallah El Sabbagh; Mackram F Eleid; Sunil V Mankad. Study design, conception and writing the manuscript: Sergio Barros-Gomes and Sunil V Mankad. Revision of the manuscript: Sergio Barros-Gomes; Abdallah, El Sabbagh; Mackram F Eleid; Sunil V Mankad.

## References

- Windecker S, Stortecky S & Meier B. Paradoxical embolism. *Journal of the American College of Cardiology* 2014 **64** 403–415. (<https://doi.org/10.1016/j.jacc.2014.04.063>)
- Prizel KR, Hutchins GM & Bulkley BH. Coronary artery embolism and myocardial infarction. *Annals of Internal Medicine* 1978 **88** 155–161.
- Hayiroğlu Mİ, Bozbeyoğlu E, Akyüz Ş, Yıldırımürk Ö, Bozbay M, Bakhshaliyev N, Renda E, Gök G, Eren M & Pehlivanoğlu S. Acute myocardial infarction with concomitant pulmonary embolism as a result of patent foramen ovale. *American Journal of Emergency Medicine* 2015 **33** 984.e5–984.e7. (<https://doi.org/10.1016/j.ajem.2014.12.025>)

Received in final form 31 July 2018

Accepted 8 August 2018